



Astar Medical Group Inc.

1108 Kane Concourse
Suite 302
Bay Harbor Islands, FL 33154
Telephone: (305)-864-6034
Fax: (305) -864-6035
astarmedical@hotmail.com

Patient: Pinkusevich Irina
Patient ID: 4254
Ordering Physician : STARIKOV

DOB: 1971-04-30
Ord#: 9737
Exam Date: 2015-08-04

ULTRASOUND OF THE RIGHT LOWER EXTREMITY:

INDICATION: Deep venous thrombosis.

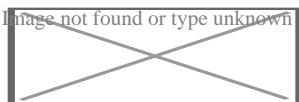
COMPARISON: None

TECHNIQUE: Sagittal and transverse real time 2-D gray scale imaging with color Doppler and duplex spectral analysis were obtained over the right lower extremity veins from the common femoral vein and greater saphenous vein to the popliteal vein.

FINDINGS: Adjacent to the greater saphenous vein there an echogenic focus with an anechoic rim and central echogenicity measuring 0.06 x 0.89 cm representing lymph node. There is an echogenic focus within the greater saphenous vein representing thrombosis of the superficial vein. There is normal augmentation of the remainder of the insonated veins of the right lower extremity.

IMPRESSION:

1. **There is no sonographic evidence of deep venous thrombosis of the insonated veins of the right lower extremity.**
2. **Thrombosis of the greater saphenous vein, which is a superficial vein, noted.**
3. **A lymph node is noted adjacent to the greater saphenous vein measuring 0.89 x 0.06 cm.**



08-06 -2015 13:26:50 : **Patient-** Pinkusevich Irina : **PID-** 4254 : **Order No-** 9737 : **DOD**
- 08-06-2015 : **DOT-** 08-06-2015 : **Ordering MD-** STARIKOV